

Content available at: <https://www.ipinnovative.com/open-access-journals>

Indian Journal of Clinical and Experimental Ophthalmology

Journal homepage: [www.ijceo.org](http://www.ijceo.org)

## Original Research Article

# To determine functional visual improvement after cataract surgery in eyes with age related macular degeneration

Deepika Joshi<sup>1,\*</sup>, Sourav Shristi<sup>2</sup><sup>1</sup>Dept. of Ophthalmology, RNT Medical College, Udaipur, Rajasthan, India<sup>2</sup>Dept. of General Medicine, RNT Medical College, Udaipur, Rajasthan, India

## ARTICLE INFO

## Article history:

Received 02-08-2021

Accepted 27-08-2021

Available online 03-01-2022

## Keywords:

Functional visual

ARMD

BCVA

## ABSTRACT

**Purpose:** To determine whether patients with Age related macular degeneration (ARMD) benefit from cataract surgery in terms of best corrected visual acuity (BCVA) and to assess impact of surgery on progression of ARMD.

**Materials and Methods:** A prospective study was carried out of patients with and without ARMD undergoing cataract surgery at our department. Patients were divided into two groups- Group A (cases) with ARMD and Group B (controls) without ARMD and other retinal pathology. BCVA of cases was recorded on day 1, day 14, 1 month and 1<sup>1</sup>/<sub>2</sub> month and compared to that of controls.

**Result:** BCVA significantly improved but markedly less than that experienced by control eyes. No increased incidence in progression to wet form of ARMD.

**Conclusion:** Cataract surgery is safe in ARMD patients with no evidence of increased complications or rates of disease advancement.

This is an Open Access (OA) journal, and articles are distributed under the terms of the [Creative Commons Attribution-NonCommercial-ShareAlike 4.0 License](https://creativecommons.org/licenses/by-nc-sa/4.0/), which allows others to remix, tweak, and build upon the work non-commercially, as long as appropriate credit is given and the new creations are licensed under the identical terms.

For reprints contact: [reprint@ipinnovative.com](mailto:reprint@ipinnovative.com)

## 1. Introduction

Age related macular degeneration (ARMD) and cataract are common diseases that frequently co- exist and advance together with aging. For patients with cataracts, cataract surgery has been shown to substantially increase functional vision and overall quality of life.<sup>1,2</sup> Due to these benefits, surgeons have expanded this operation to patients with AMD in hopes of conferring similar benefits. There is controversy regarding the possible benefits or risks of cataract surgery in eyes with AMD. Some studies have suggested that cataract surgery may hasten the progression of AMD, although recent reports have revealed that cataract surgery may be beneficial in this group of patients.<sup>3</sup>

Cataract and AMD share common risk factors, such as smoking and nutrition that could cause them to progress

simultaneously. In addition, inflammatory factors have been implicated in the causation of AMD and it is feasible that inflammation occurring after cataract surgery could cause worsening of macular degeneration. Moreover, the replacement of the natural lens with an artificial lens could be associated with increased exposure to light and damaging ultraviolet rays.

The primary endpoint of this study was to determine if eyes with AMD had as much overall functional visual improvement after cataract surgery as eyes without retinal pathology. Secondary endpoints included preoperative and postoperative BCVAs, and correlation between preoperative BCVA (preBCVA) and postoperative visual function.

## 2. Materials and Methods

A prospective, randomized study was conducted in patients with and without ARMD having visually significant cataract

\* Corresponding author.

E-mail address: [doc.deepikajoshi@gmail.com](mailto:doc.deepikajoshi@gmail.com) (D. Joshi).

who were presented to or referred to ophthalmology outdoor and underwent planned extracapsular cataract extraction by phacoemulsification with PCIOL implantation method to evaluate functional visual outcome after cataract surgery and compare their outcomes with controls without retinal pathology between June 2016 and October 2017.

A total of 100 eyes of 100 patients undergoing cataract surgery by phacoemulsification with PCIOL implantation were included. A written informed consent with regards to participation in the study was taken from the patients after providing them with a thorough explanation. Preoperatively, all patients underwent a complete ophthalmologic examination.

By randomization patients were divided into two groups:

Group A (Cases): 50 patients with ARMD

Group B (Controls): 50 patients without any retinal pathology.

All patients received eye drop moxifloxacin 0.3% QID for three days and tablet ciprofloxacin 500mg BD for one day preoperatively. On the day of surgery 2 hours before surgery patients were dilated using Eye drop Tropicamide + phenylephrine

Eye drop Cyclopentolate

Eye drop Flurbiprofen

Postoperatively eye was covered for one day. Patients in both groups received common treatment comprising of – moxifloxacin + dexamethasone eye drop 6 times a day. Carboxy methyl cellulose eye drop 4 times a day, Nepafenac eye drop 3 times a day, Tab. Ciprofloxacin 500 mg BD for 5 days and tab Ibuprofen 400 mg as required. Postoperatively patients underwent a complete ophthalmologic examination including –

1. Best corrected visual acuity
2. Intraocular pressure
3. Optical coherence tomography
4. Fundus examination
5. Slit lamp biomicroscopy on day 1, day 14, 1 month and 1 ½ month

Patients having following retinal pathologies were excluded from this study:

1. Diabetic retinopathy
2. Hypertensive retinopathy
3. Macular oedema
4. Central retinal artery and vein occlusion
5. Branched retinal artery and vein occlusion
6. Central serous chorioretinopathy
7. Eales disease or any other noted on the pre-op dilated fundus examination.

### 3. Results

From June 2016 to October 2017, 118 patients were enrolled in the study out of which 100 completed the study and 18

were lost to follow up. 50 were in group A (cases) and 50 in group B (controls). As shown in Table 1 the total number of patients completing the study in both the groups were equal and therefore both the study arms were comparable with regards to sample size.

Table 2 shows that in both the study groups most of the patients were > 50 years of age.

4 percent of study population was < 50 years of age and 96 percent of study population was > 50 years of age. 59 percent of study population was male while 41 percent were females as shown in Figure 1.

Table 3 shows the change in visual acuity with the passage of time as calculated by taking mean of the logMAR visual acuities of each day. The difference between the two groups with regards to the change in logMAR visual acuity on postoperative day 1 was statistically significant as p - value is < 0.05 and on postoperative days 14, 30 and 45 was not statistically significant as p - value remained > 0.05).

Both preoperative and postoperative BCVA (logMAR) was analysed as shown in Table 2 . Preoperative BCVA (logMAR) was not significantly different from controls. Postoperatively, BCVA significantly improved but markedly less than that experienced by control eyes.

The change in intraocular pressure with passage of time was calculated by taking a mean of the intraocular pressure of each day as shown in Table 4. The mean intraocular pressure remains within 13 to 16 mmHg with a slight peak on POD1 for both the groups (Table 3). The difference between the two groups with respect to IOP is not statistically significant as the p-value remained >0.05.

There was no incidence of choroidal-neovascularization (wet ARMD) in our study as confirmed by OCT.

**Table 1:** Sample size

	Group A (Cases)	Group B (Controls)	Total
Total enrolled	58	60	118
Lost to follow up	8	10	18
Completed	50	50	100

**Table 2:** Demographics

Age (years)	Group A (cases)	Group B (controls)	Total
<= 50	1 (2.0%)	3 (6.0%)	4 (4.0%)
>50	49 (98.0%)	47 (94.0%)	96 (96.0%)

### 4. Discussion

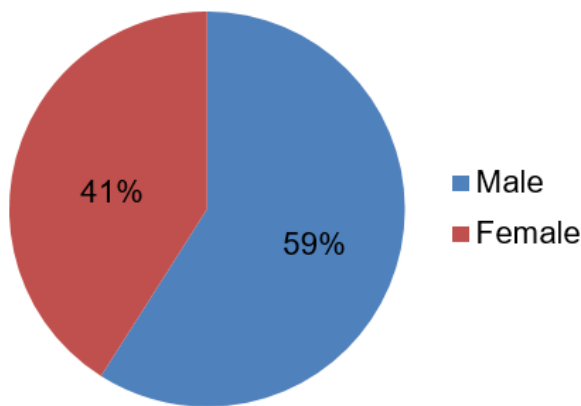
The coexistence of cataract and age related macular degeneration (AMD) is not unusual, especially in the elderly. The outcome of cataract surgery in these cases depends on the effect of AMD on vision. Multiple studies have been conducted where the authors have compared the

**Table 3:** Visual acuity (logMAR)

	Pre op	POD 1	POD 14	POD 30	POD 45
Group A (Cases)	0.506	0.178	0.018	0.006	0.002
Group B (Controls)	0.462	0.012	0.002	0.000	0.000
P value	0.304	0.00	0.082	0.080	0.320

**Table 4:** Intraocular pressure (mmHG)

	PRE OP	POD 1	POD 14	POD 30	POD 45
Group A	13.838	16.188	16.834	13.236	12.824
Group B	14.002	16.834	14.326	13.082	13.434
P value	0.724	0.052	0.366	0.632	0.171

**Fig. 1:** Demographics

outcome of cataract patients with AMD to that of cataract patients with no vision threatening ocular comorbidity, and analysed possible predictors of good or poor outcome.

In our study cases having increased preoperative BCVA also have increased postoperative BCVA and those having decreased BCVA have lesser improvement in visual outcome after cataract surgery while in controls postoperative BCVA was found to have no association with preoperative BCVA. These findings were consistent with the study conducted by Stock, vollman, DE, Baze EF, Chomsky AS.<sup>4</sup>

Monestam E & Lundqvist B conducted longitudinal cohort study which concluded that patients with signs of AMD at cataract surgery had a longitudinally worse visual outcome than patients without clinical signs of AMD.<sup>5</sup> However, in our study cases have improved BCVA although it is less than that experienced by controls therefore there is no reason to discourage patients with concurrent visually significant cataract and ARMD from having surgery.

Study conducted by Hooper et al concluded that no increased short-term risk of progression of AMD to CNV in high-risk fundi following uncomplicated phacoemulsification surgery was found. A low threshold for performing preoperative imaging in patients with AMD,

especially in those with exudative AMD in the fellow eye, to exclude undetected CNV is recommended. Provided there is no CNV, there are distinct benefits of cataract surgery in people with early AMD.<sup>6</sup> Dong et al has document that cataract surgery does not increase the risk of ARMD progression.<sup>7</sup> Our study mirrored the findings by Hooper and Dong.

Our findings seem to be consistent with an observational study conducted by Lundstorm et al which concluded that subjects with various stages of dry ARMD and cataract improved their self assessed visual function and satisfaction with vision significantly after cataract extraction.<sup>8</sup>

Study conducted by Lamouruex et al stated that cataract surgery is justified in patients with early AMD. It brings significant improvements in visual acuity, aspects of daily living, and overall QoL.<sup>9</sup>

Armbrecht, Findlay et al.<sup>10</sup> documented that patients with mild and moderate degrees of ARMD do benefit from cataract surgery and the benefits are greater in patients with moderate degrees of lens opacity.<sup>3</sup> Our study mirrored the findings by Lamouruex and Armbrecht.

Our results agree with those of previous studies looking at improvements in BCVA and functional visual improvement. Also, our results give a reference for cataract surgeons and AMD patients to base expectations of both the absolute and relative benefits of undergoing cataract surgery with AMD.

## 5. Conclusion

Cataract surgery is safe in AMD patients with no evidence of increased complications or rates of disease advancement (especially conversion to wet ARMD) postoperatively. Cataract surgery on eyes with AMD led to increased visual function; however, increases were significantly less when compared with patients without retinal pathology as in our study.

## 6. Source of Funding

None.

## 7. Conflict of Interest

The authors declare no conflict of interest.

## References

1. Brown GC, Brown MM, Menezes A, Busbee BG, Lieske HB, Lieske PA. Cataract surgery cost utility revisited in 2012: A new economic paradigm. *Ophthalmology*. 2013;120:2367–76.
2. Chandrasekaran S, Wang JJ, Rochtchina E, Mitchell P. Change in health-related quality of life after cataract surgery in a population-based sample. *Eye (Lond)*. 2008;22:479–84.
3. Armbrecht AM, Findlay C, Kaushal S, Aspinall P, Hill AR, Dhillon B. Is cataract surgery justified in patients with age related macular degeneration? A visual function and quality of life assessment. *Br J Ophthalmol*. 2000;84:1343–8.
4. Stock MV, Vollman DE, Baze EF, Chomsky AS, Daly MK, Lawrence MG. Functional visual outcome after cataract surgery in eyes with age related macular degeneration. *Invest Ophthalmol Vis Sci*. 2015;56(4):2536–40. doi:10.1167/iovs.14-16069.
5. Monestam E, Lundqvist B. Long-term visual outcome after cataract surgery: comparison of healthy eyes and eyes with age-related macular degeneration. *J Cataract Refract Surg*. 2012;38:409–14.
6. Hooper CY, Lamoureux EL, Lim L, Fraser-Bell S, Yeoh J, Harper CA, et al. Cataract surgery in high risk age-related macular degeneration: a randomized controlled trial. *Clin Exp Ophthalmol*. 2009;37:570–6.
7. Dong LM, Stark WJ, Jefferys JL, Al-Hazzaa S, Bressler SB, Solomon SD, et al. Progression of age-related macular degeneration after cataract surgery. *Arch Ophthalmol*. 2009;127:1412–9.
8. Lundstrom M, Brege KG, Floren I, Lundh B, & Thorburn WSU. Cataract surgery and quality of life in patients with age related macular degeneration. *Br J Ophthalmol*. 2002;86:1330–5.
9. Lamoureux EL, Hooper CY, Lim L, Pallant JF, Hunt N, Keeffe JE, et al. Impact of cataract surgery on quality of life in patients with early age-related macular degeneration. *Optom Vis Sci*. 2007;84:683–8.
10. Armbrecht AM, Findlay C, Aspinall PA, Hill HR, Dhillon B. Cataract surgery in patients with age-related macular degeneration: one-year outcomes. *J Cataract Refract Surg*. 2003;29(4):686–93.

## Author biography

**Deepika Joshi**, Resident

**Sourav Shristi**, Resident

**Cite this article:** Joshi D, Shristi S. To determine functional visual improvement after cataract surgery in eyes with age related macular degeneration. *Indian J Clin Exp Ophthalmol* 2021;7(4):655-658.