

Content available at: <https://www.ipinnovative.com/open-access-journals>

Indian Journal of Clinical and Experimental Ophthalmology

Journal homepage: [www.ijceo.org](http://www.ijceo.org)

## Original Research Article

## To measure angle of anterior chamber using Topcon SD-OCT: A new technique

Nida Khan<sup>1,\*</sup>, Prakash Agarwal<sup>2</sup>, Saroj Gupta<sup>3</sup>, Khalid Khan<sup>4</sup><sup>1</sup>Dept. of Ophthalmology, Indian Institute of Medical Sciences & Research Centre, Aurangabad, Maharashtra, India<sup>2</sup>Dept. of Ophthalmology, RKDF Medical College & Research Center, Bhopal, Madhya Pradesh, India<sup>3</sup>Dept. of Ophthalmology, All Indian Institute of Medical Sciences & Research Center, Bhopal, Madhya Pradesh, India<sup>4</sup>Dept. of Ophthalmology, Chirayu Medical College, Bhopal, Madhya Pradesh, India

## ARTICLE INFO

## Article history:

Received 10-05-2021

Accepted 18-05-2021

Available online 30-09-2021

## Keywords:

Angle measurement

New technique

Topcon-SD-OCT

## ABSTRACT

**Background:** The proposed new method of measuring angle of anterior chamber is an effective method of measuring the angles. Identification of narrow anterior chamber angle is important for glaucoma screening and prophylactic treatment prevents acute angle closure glaucoma event.

**Aim of this study** was to measure the angle of anterior chamber using Topcon spectral domain optical coherence tomography (SD OCT).

**Materials and Methods:** In this cross-sectional study 120 normal subjects above the age of 40 years were enrolled. The study was done at the tertiary health care center of central Indian. All volunteers had visual acuity of at least 6/9 with no ocular diseases. Using OCT the angle opening distance (AOD-500), trabecular-iris angle (TIA) and trabecular-iris space area (TISA-500) were measured.

**Result:** In this study the mean AOD was 0.430  $\mu\text{m}$  in nasal and 0.433  $\mu\text{m}$  in temporal quadrant. The mean TISA in nasal was 0.405  $\mu\text{m}$  and temporal quadrant was 0.408  $\mu\text{m}$ . While the mean trabecular iris angle (TIA) was 26.9° in nasal and 26.01° in temporal quadrant.

**Conclusion:** The study proved that the proposed method of measuring AOD, TISA, TIA is the effective method as the Topcon-2000 OCT does not have any inbuilt software like that of other ASOCT machines.

This is an Open Access (OA) journal, and articles are distributed under the terms of the [Creative Commons Attribution-NonCommercial-ShareAlike 4.0 License](https://creativecommons.org/licenses/by-nc-sa/4.0/), which allows others to remix, tweak, and build upon the work non-commercially, as long as appropriate credit is given and the new creations are licensed under the identical terms.

For reprints contact: [reprint@ipinnovative.com](mailto:reprint@ipinnovative.com)

## 1. Introduction

Gonioscopy is the current reference standard for the assessment of the anterior chamber angle. The technique is semi quantitative and subject to inter- and intraobserver discrepancies. Anterior segment optical coherence tomography (AS-OCT) is a new method of imaging the angle. AS-OCT uses the principle of low-coherence interferometry to assess ocular tissues and may be used to obtain quantitative morphometric information. It has been shown that compared with normal eyes, eyes with occludable angles and with PACG have smaller anterior

chamber depth (ACD), thicker lenses, and shorter axial length.<sup>1–8</sup>

Previously used methods for evaluation of the anterior chamber angle of the eye, such as slit-lamp biomicroscopy, or gonioscopy, are known to be subjective. Ultrasound biomicroscopy (UBM) reportedly allows for a quantitative measurement of the anterior chamber angle.<sup>9–12</sup> However, due to the fact that UBM is a contact measurement, the utilization of this method is limited to patient screening, and cannot be used for immediate postoperative cases.<sup>13–20</sup> ASOCT have several advantages over gonioscopy as it is rapid, non-contact (can be used in post operative cases), quantitative, qualitative, no interobserver variability, reproducible, it provide rapid estimation of the various

\* Corresponding author.

E-mail address: [dr.nidak88@gmail.com](mailto:dr.nidak88@gmail.com) (N. Khan).

anterior segment parameters, including corneal thickness, anterior chamber depth and also helps in examination of posterior segment parameters and provide its measurement.

## 2. Materials and Methods

### 2.1. Material

120 Consecutive patients (240 eyes) presenting to ophthalmology out patient department of tertiary health care center in the central India were enrolled in a cross-sectional study. All patients underwent comprehensive ocular examination with included best corrected visual acuity, slit lamp, dilated fundus examination, gonioscopy, intraocular pressure (IOP) measured by Goldmann applanation tonometer, evaluation of angle (i.e. AOD, TISA, TIA) of anterior chamber with SD-OCT was done. The duration of study was one year six months. The data were analyzed by using SPSS 16.0. This study was approved from the research and ethics committee of the institute. Informed consent was obtained.

Inclusion criteria were age >40 years, patients with written informed consent.

Exclusion criteria were patient with Intumescent, mature and hyper mature cataract, high myopia, glaucoma, ocular trauma, major intra ocular eye disease.

The patients above 40 years of age is taken as angle of anterior chamber gets narrower as the age increases.

### 2.2. Methods of evaluation

Eyes that fulfilled both exclusion and inclusion criteria were selected for analysis. After complete clinical examination details of the patient including age, sex, race (Asian) specific examination modes were selected.

### 2.3. Method of measurement of angle of anterior chamber (AOD, TIA, TISA)

Scleral spur identification is the first step for calculating anterior chamber parameters by OCT. Inbuilt digital calipers of Topcon OCT machine are then used to mark a point on posterior surface of cornea 500 microns anterior to sclera spur. Now a transparent plastic sheet is placed on the computer screen and these 2 points (From scleral spur and posterior surface of cornea i.e. 500 microns) are marked on the sheet. Using digital caliper of Topcon OCT machine a line is drawn perpendicular from posterior corneal point to the surface of iris. This line is AOD 500. A line parallel to AOD500 is drawn from sclera spur to surface of iris. The 2 points on the iris are connected to each other. The quadrilateral (trapezoid) thus formed is called TISA. All these points are marked on the transparent sheet by tracing method. Now the plastic sheet is removed from the screen and using normal scale the lines along cornea and iris and drawn backwards to meet at a point in the angle depth. This

defines the apex of anterior chamber angle i.e. TIA. The area of trapezoid (TISA) is measured with the help of applying formula of trapezoid i.e.  $\text{area} = (b_1 + b_2/2)h$  where  $b_1$  height of 1<sup>st</sup> base  $b_2$  is height of 2<sup>nd</sup> base and  $h$  is height of trapezoid.

## 3. Results

In our study we have studied the AS-OCT parameters among normal subjects and results of 120 subjects (240 eyes) were analyzed. The mean age of subjects was 53.94 years with a SD  $\pm$  8.05 years. There were 61 males and 59 females.

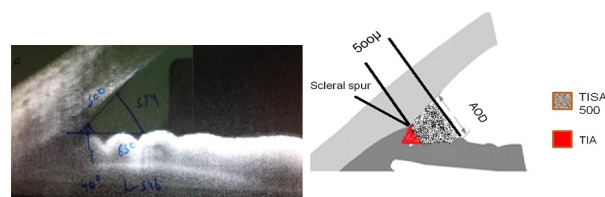


Fig. 1:

**Table 1:** Comparison of different parameters on OCT nasal & temporal quadrant between Male and Female subjects

Parameter	Mean nasal	Mean temporal
AOD $\mu\text{m}$ Male	0.4583	0.4613
AOD $\mu\text{m}$ Female	0.4175	0.4142
TISA $\mu\text{m}$ Male	0.3847	0.4569
TISA $\mu\text{m}$ Female	0.4258	0.4926
TIA (Deg) Male	28.2626	27.3979
TIA (Deg) Female	26.3434	25.5054

**Table 2:** Mean parameters of nasal and temporal quadrant on OCT

Parameter	Mean Nasal	Mean Temporal
AOD $\mu\text{m}$	$0.430 \pm 0.137$	$0.433 \pm 0.177$
TISA $\mu\text{m}$	$0.405 \pm 0.261$	$0.408 \pm 0.278$
TIA (Deg)	$26.904 \pm 7.691$	$26.016 \pm 7.781$

## 4. Discussion

Angle assessment is essential for determining type of glaucoma based on angles. Although gonioscopy has been considered as the gold standard for characterizing the ACA, it is subjective and requires the expertise. Placement of a contact lens on the eye and localized corneal compression can cause fluid displacement and widening of the angle. Light intensity can alter grading of the angle. Imaging with OCT defines ACA characteristics in an objective manner avoiding contact with the globe with contact lens. These images can be analysed qualitatively and quantitatively. As a

**Table 3:** Comparative data of our study with OCT values from other studies

	Number of subjects	Quadrant	Mean AOD 500 $\mu$	Mean TISA 500 $\mu$	Mean TIA degree
Present study	120	Nasal	0.43	0.40	26.90
		Temporal	0.43	0.40	26.01
Yuko Maruyama	130	Nasal	0.42	0.16	Not done
		Temporal	0.44	0.17	Not done
D S Grewal	265	Nasal	0.48	0.33	Not done
		Temporal	0.49	0.32	Not done
Nishant Amer Singh	239	Nasal	0.27	0.11	Not done
		Temporal	0.26	0.10	Not done
Sunita Radhakrishnan	43	Nasal	0.44	0.15	Not done
		Temporal	0.44	0.17	Not done

result, it is a quick, easily tolerated procedure for the patient and there is also less distortion of angle morphology due to lack of globe manipulation.<sup>21</sup>

Yuko Maruyama et al studied an AS-OCT in 130 subjects where they found mean AOD nasal was 0.42  $\mu$ m and mean AOD temporal was 0.44  $\mu$ m. While in our study the mean AOD nasal and temporal values are 0.43  $\mu$ m so, it is showing correlation.<sup>22</sup>

D S Grewal et al. did a study using SD-ASOCT (spectral domain ASOCT) in 265 eyes where the mean AOD nasal was 0.48  $\mu$ m and AOD temporal was 0.49  $\mu$ m. While the value of TISA nasal was 0.33  $\mu$ m and temporal was 0.32  $\mu$ m.<sup>23</sup> These values are correlating with the values of our study (nasal and temporal AOD 0.43  $\mu$ m, TISA nasal and temporal 0.40  $\mu$ m).

Radhakrishnan et al. studied 43 subjects and found mean AOD nasal and temporal was 0.44  $\mu$ m and mean TISA nasal was 0.15  $\mu$ m and TISA temporal was 0.17  $\mu$ m.<sup>24</sup>

Amersingh et al. in their study of 239 subjects they found mean value of AOD nasal was 0.27  $\mu$ m and temporal was 0.26  $\mu$ m while mean TISA nasal was 0.11  $\mu$ m and TISA temporal was 0.10  $\mu$ m.<sup>25</sup>

In our study the angle measured (in degrees) by gonioscopy correlated with TIA (in degrees) measured by ASOCT. This is comparable with the study of Nolan WP et al. where all patients who have closed angles on gonioscopy also showed closed angles on ASOCT.<sup>26</sup>

## 5. Limitation

Small sample size remains the limitation of our study. With more number of patients, a normative value and cut off values for occludable angle can be found out. Also, the scleral spur of superior and inferior quadrants could not be identified in the model of the OCT used in the study.

## 6. Conclusion

Anterior segment imaging plays an important role in diagnosis and management of glaucoma. However due to lack of measurement tools(calipers) in OCT machine,

in-built software and standard measurement protocols, the parameters such as AOD, TISA and TIA are not discussed in most of these studies. The study proved that the proposed method of measuring AOD,TISA,TIA is the effective method as the Topcon-2000 does not have any inbuilt software like that of other asoctmachines so in such condition it provides a good information for both anterior and posterior segment examination with the help of single machine.

## 6.1. Clinical significance

The study proved that this method of measuring angle of anterior chamber is an effective method of measuring the angles. Anterior segment imaging plays an important role in diagnosis and management of glaucoma. Identification of narrow anterior chamber angle is important for glaucoma screening and prophylactic treatment prevents acute angle closure glaucoma event. So with the help of single machine we can get information of both anterior & posterior segment.

## 7. Source of Funding

The authors have no funding or support to disclose for this study.

## 8. Conflict of Interest

None.

## References

1. Saxena S, Agrawal PK, Pratap VB, Nath R. Anterior chamber depth and lens thickness in primary angle closure glaucoma: a case control study. *Indian J Ophthalmol.* 1993;41(2):71–3.
2. Sihota R, Gupta V, Agrawal HC, Pandey RM, Deepak KK. Comparison of symptomatic and asymptomatic, chronic, primary angle closure glaucoma, open angle glaucoma and controls. *J Glaucoma.* 2000;9(3):208–13.
3. Sihota R, Lakshmaiah NC, Agrawal HC, Pandey RM, Titiyal JS. Ocular parameters in the subgroups of angle closure glaucoma. *Clin Exp Ophthalmol.* 2000;28(4):253–8.
4. Sihota R, Dada T, Gupta R, Lakshminarayan P, Pandey RM. Ultrasound biomicroscopy in the subtypes of primary angle closure glaucoma. *J Glaucoma.* 2005;14(5):387–91.

5. Panek WC, Christensen RE, Lee DA, Fazio DT, Fox LE, Scott TV. Biometric variables in patients with occludable anterior chamber angles. *Am J Ophthalmol*. 1990;110(2):185-8.
6. Tomlinson A, Leighton DA. Ocular dimensions in the heredity of angle closure glaucoma. *Br J Ophthalmol*. 1973;57(7):475-86.
7. Lee DA, Brubaker RF, Illstrup DM. Anterior chamber dimensions in patients with narrow angles and angle closure glaucoma. *Arch Ophthalmol*. 1984;102(1):46-50.
8. George R, Paul PG, Baskaran M. Ocular biometry in occludable angles and angle closure glaucoma: a population based survey. *Br J Ophthalmol*. 2003;87(4):399-402.
9. Pavlin CJ, Foster FS. Ultrasound biomicroscopy. High-frequency ultrasound imaging of the eye at microscopic resolution. *Radiol Clin North Am*. 1998;36(6):1047-58.
10. Sakata LM, Wong TT, Wong HT. Comparison of Visante and slit-lamp anterior segment optical coherence tomography in imaging the anterior chamber angle. *Eye (Lond)*. 2010;24(4):578-87.
11. Urbak SF, Pedersen JK, Thorsen TT. Ultrasound biomicroscopy. II. Intraobserver and interobserver reproducibility of measurements. *Acta Ophthalmol Scand*. 1998;76(5):546-9.
12. Tello C, Liebmann J, Potash SD, Cohen H, Ritch R. Measurement of ultrasound biomicroscopy images: intraobserver and interobserver reliability. *Invest Ophthalmol Vis Sci*. 1994;35(9):3549-52.
13. Grulkowski I, Gora M, Szkulmowski M, Gorczynska I, Szlag D, Marcos S, et al. Anterior segment imaging with Spectral OCT system using a high-speed CMOS camera. *Opt Express*. 2009;17(6):4842-58.
14. Garcia JP, Rosen RB. Anterior segment imaging: optical coherence tomography versus ultrasound biomicroscopy. *Ophthalmic Surg Lasers Imaging*. 2008;39(6):476-84.
15. Sakata LM, Lavanya R, Friedman DS. Comparison of gonioscopy and anterior segment ocular coherence tomography in detecting angle closure in different quadrants of the anterior chamber angle. *Ophthalmology*. 2008;115(5):769-74.
16. Dada T, Sihota R, Gadia R, Aggarwal A, Mandal S, Gupta V. Comparison of anterior segment optical coherence tomography and ultrasound biomicroscopy for assessment of the anterior segment. *J Cataract Refract Surg*. 2007;33(5):837-40.
17. Leung CK, Li H, Weinreb RN. Anterior chamber angle measurement with anterior segment optical coherence tomography: a comparison between slit lamp OCT and Visante OCT. *Invest Ophthalmol Vis Sci*. 2008;49(8):3469-74.
18. Bailey MD, Sinnott LT, Mutti DO. Ciliary body thickness and refractive error in children. *Invest Ophthalmol Vis Sci*. 2008;49(10):4353-60.
19. Pekmezci M, Porco TC, Lin SC. Anterior segment optical coherence tomography as a screening tool for the assessment of the anterior segment angle. *Ophthalmic Surg Lasers Imaging*. 2009;40(4):389-98.
20. Khor WB, Sakata LM, Friedman DS. Evaluation of scanning protocols for imaging the anterior chamber angle with anterior segment-optical coherence tomography. *J Glaucoma*. 2010;19(6):365-8.
21. Quek DLK, Nongipur ME, Perera SA, Aung T. Angle imaging: advances and challenges. *Indian J Ophthalmol*. 2011;59:69-75.
22. Maruyama Y, Mori K, Ikeda Y, Ueno M, Kinoshita S. Morphological analysis of age-related iridocorneal angle changes in normal and glaucomatous cases using anterior segment optical coherence tomography. *Clin Ophthalmol*. 2014;8:113-8. doi:10.2147/OPHTH.S52370.
23. Grewal DS, Brar GS, Jain R. Comparison of Scheimpflug imaging and spectral domain anterior segment optical coherence tomography for detection of narrow anterior chamber angles. *Eye (Lond)*. 2011;25:603-11.
24. Radhakrishnan S, Goldsmith J, Huang D, Westphal V, Dueker DK, Rollins AM, et al. Comparison of optical coherence tomography and ultrasound biomicroscopy for detection of narrow anterior chamber angles. *Arch Ophthalmol*. 2005;123(8):1053-9.
25. Amerasinghe N, Foster PJ, Wong TY, Htoon HM, He M, Shen SY, et al. Variation of angle parameters in asians: an anterior segment optical coherence tomography study in a population of singaporemalays. *Invest Ophthalmol Vis Sci*. 2009;50(6):2626-31.
26. Nolan WP, See JL, Chew PTK, Friedman DS, Smith SD. Detection of primary angle closure using anterior segment optical coherence tomography in Asian eyes. *Ophthalmology*. 2007;114(1):33-9.

### Author biography

**Nida Khan**, Assistant Professor

**Prakash Agarwal**, Professor

**Saroj Gupta**, Additional Professor

**Khalid Khan**, Associate Professor

**Cite this article:** Khan N, Agarwal P, Gupta S, Khan K. To measure angle of anterior chamber using Topcon SD-OCT: A new technique. *Indian J Clin Exp Ophthalmol* 2021;7(3):537-540.